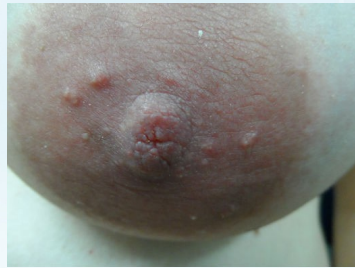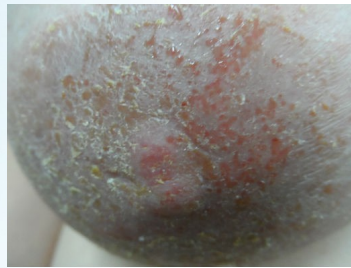


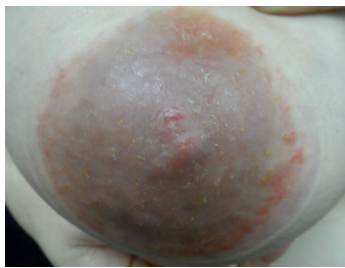### Lactation Consultant:



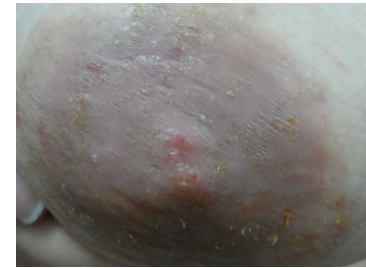
1. the unaffected nipple



2. the weeping eczema  
as it was when the manuka honey breast pad was applied. A skin swab cultured staph aureus.



3. the affected nipple after 48 hours. We decided the pad was too small, so cut up another pad in a spiral shape to fit around the periphery.



4. the affected nipple after another 48 hours. Although the mother thought this was the most healing she had achieved so far, we thought it was time for a brief trial of hydrocortisone cream.

After months of other treatments, we got a result like no other within 4 days.

